EMO GVM CENTRO CUORE COLUMBUS

New York Transcatheter Valves 2019
PATIENT FOCUSED EVIDENCE-BASED APPROACH

GVM CARE & RESEARCH

New York City: 5 December 2019

CHALLENGING TRANSCATHETER VALVULAR TECHNIQUES

Managing complications of TAVR

Speaker – 10'

Antonio Colombo

EMO-GVM, Centro Cuore Columbus, Milan, Maria Cecilia Hospital ,Cotignola (RA) and GVM Laboratories, Italy

Nothing to disclose

In very high risk patients we can expect and hopefully successfully treat complications

In medium and low risk patients we should not expect complications

Hard End Points

EMO GVM CENTRO

GVM CARE & RESEARCH

Vascular complications

Annular rupture and intracardial holes

Coronary occlusion

LV perforation

Strokes etc.

Vascular complications

They can occur with any valve.
In general the smaller the introducer the lowest the risk.

The bottom line is that even when facing the most dramatic vascular complication such as ileo-femoral vessel rupture, abdominal aorta balloon occlusion can control the complication and allow strategic solutions

Right Femoral Approach

Preprocedural CT report tortuosity of iliac arteries, more calcified left side, diameter > 8mm, no stenosis

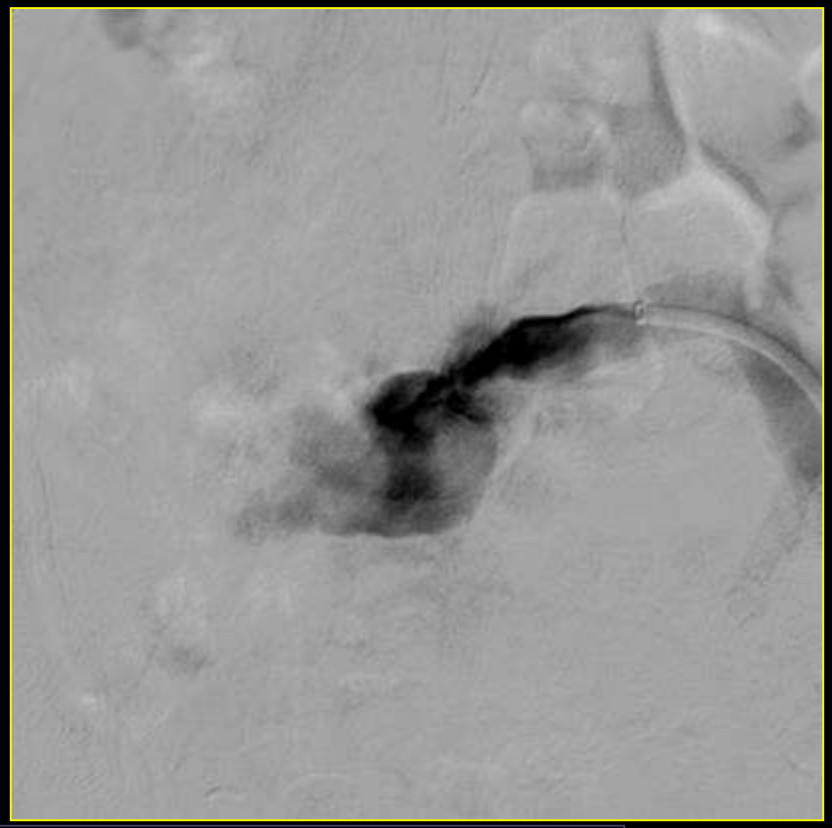

Rupture of left common iliac artery
during attempts to cross-over from left to right femoral artery
to prepare and protect right approach (18 French)

Patient went immediately in shock requiring cardiac massage, liquids, adrenaline, intubation ..

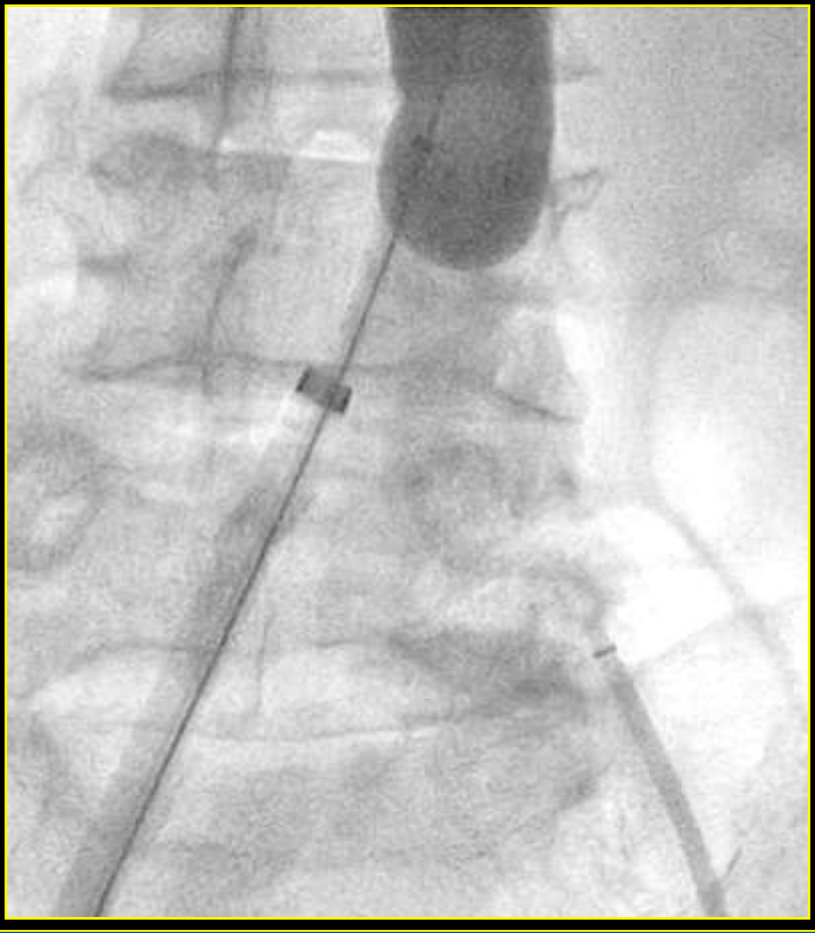

Immediate positioning of aortic occlusion balloon

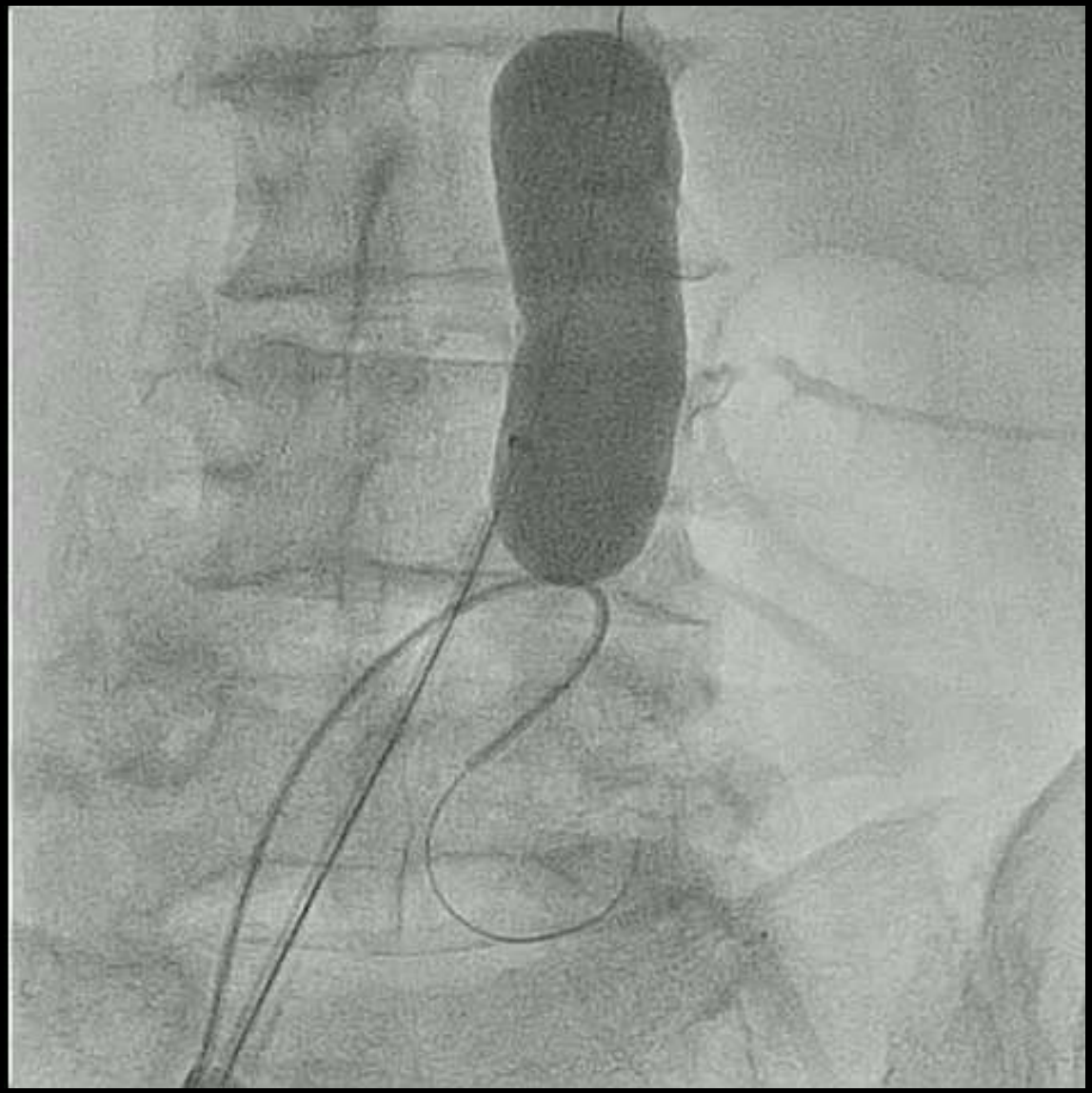

CrossOver (right to left): terumo wire and Simmons catheter

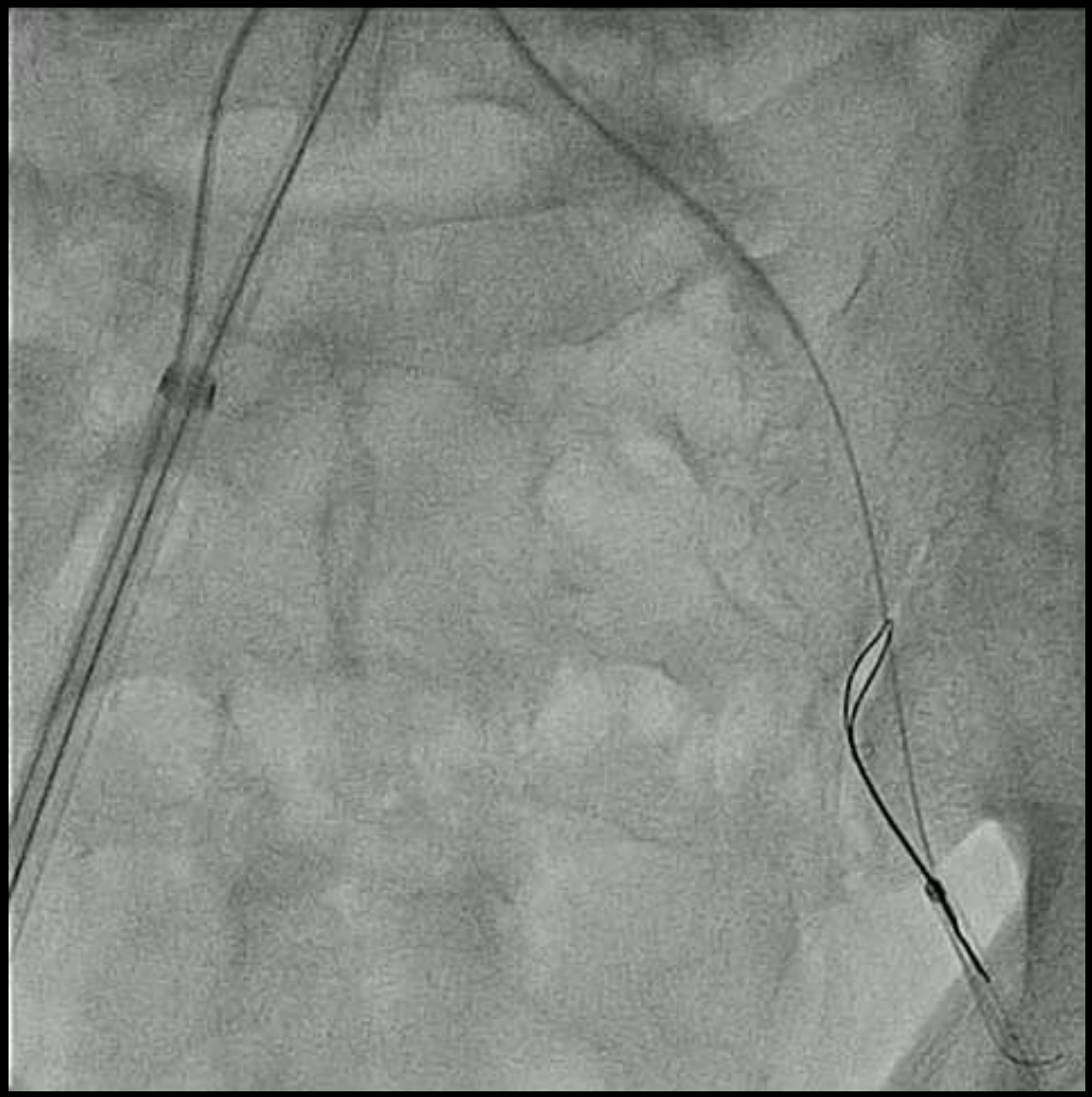

Lazoo to capture terumo and left exteriorization of Simmons

Fluency 12x80mm
Left approach

Rupture of a small vessel

Difficult to be localized by angio, CT is needed

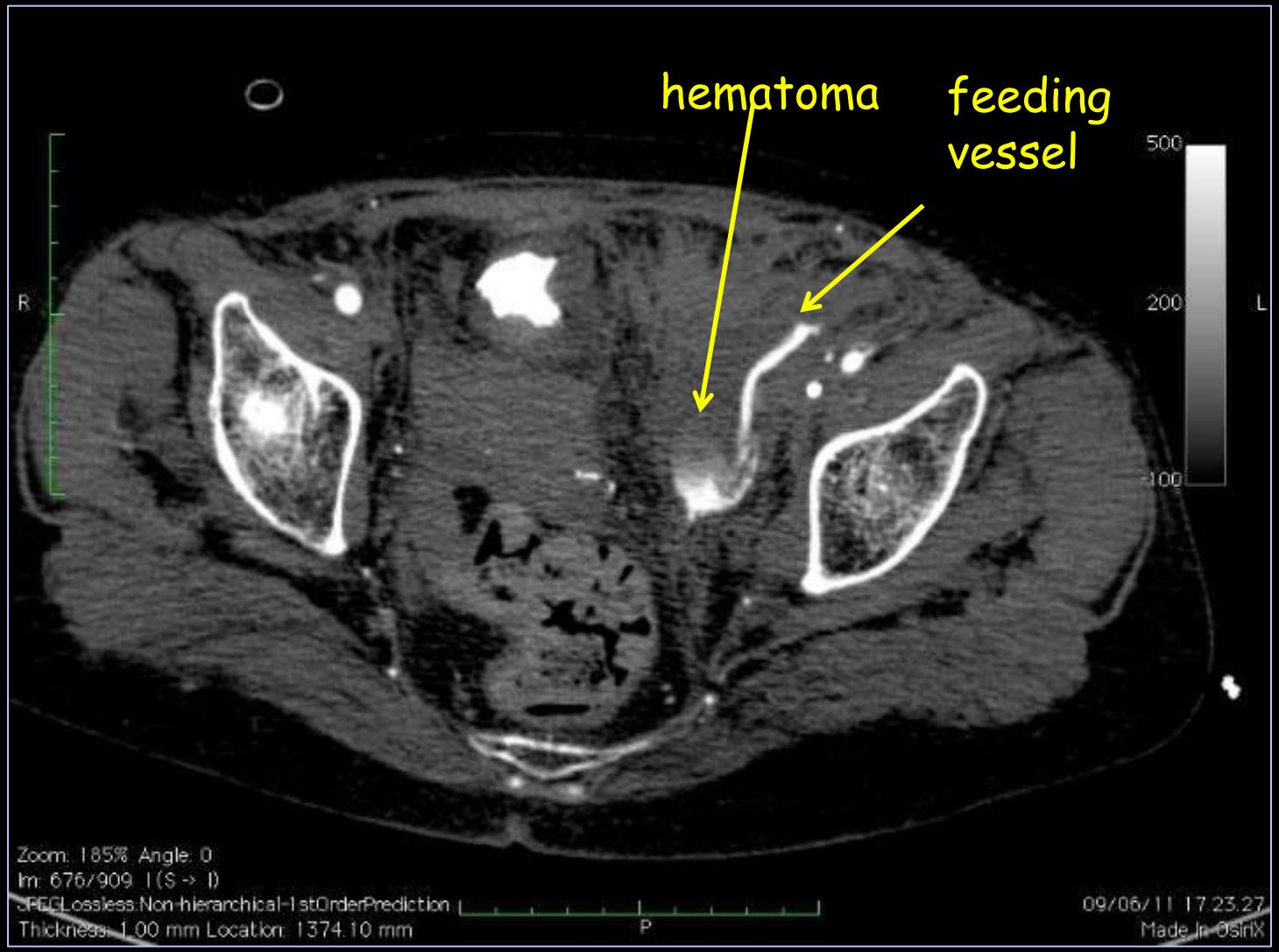

Annular rupture

Accurate and precise measurement of the aortic annulus should prevent this complication

In some conditions it may not be possible to obtain accurate and reliable measurements

Valves exposed to this risk:

Balloon expandable valves

Valves requiring postdilatation

Valves requiring predilatation

Active expanding valves

Rupture of LV outflow-tract

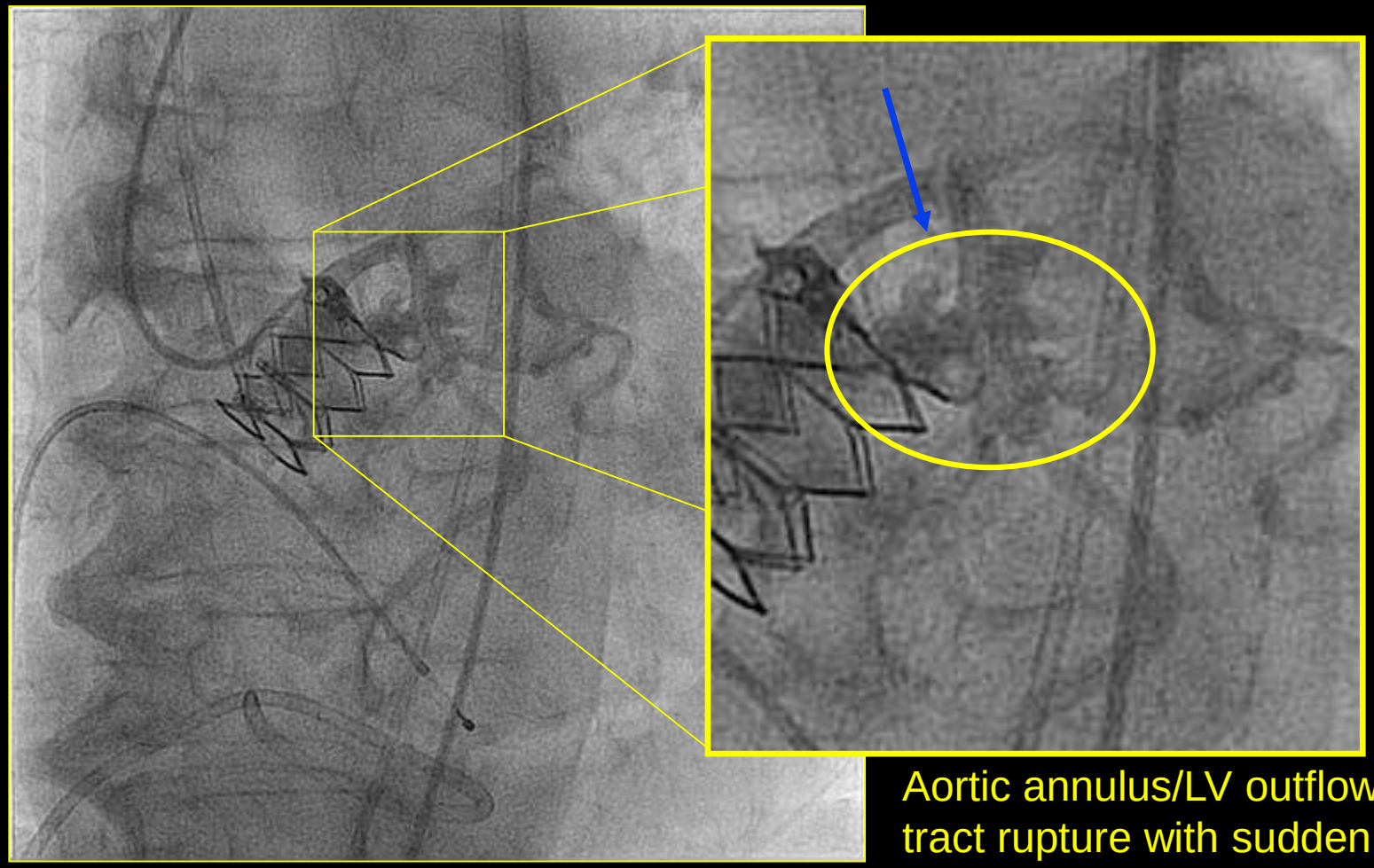

Aortic annulus/LV outflow tract rupture with sudden hemodynamic collapse

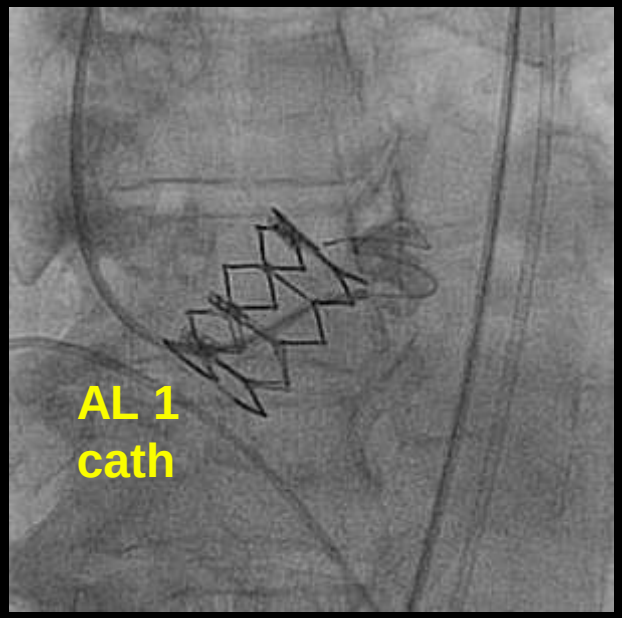

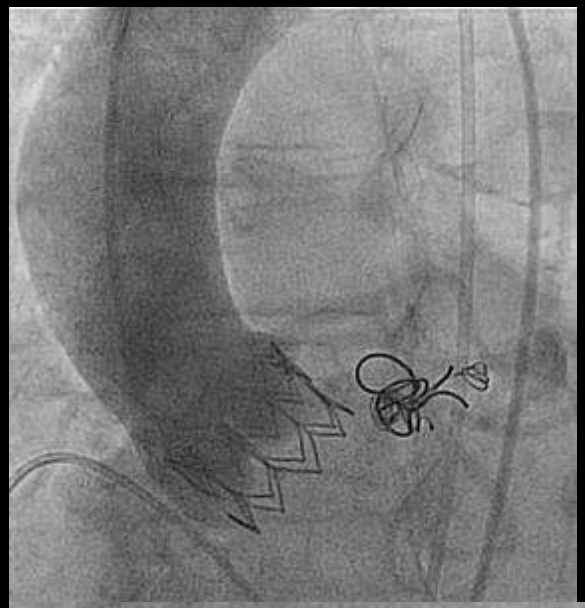

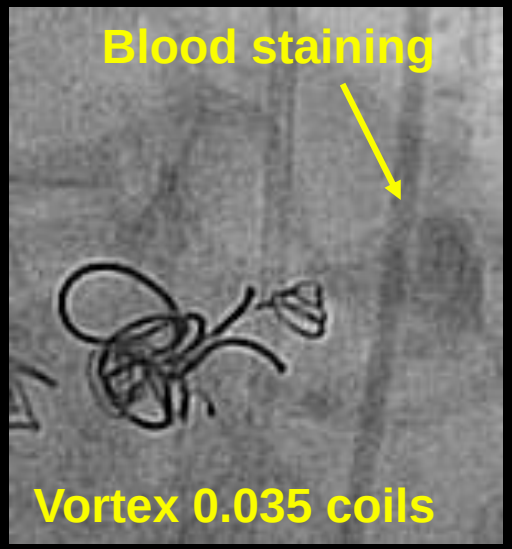

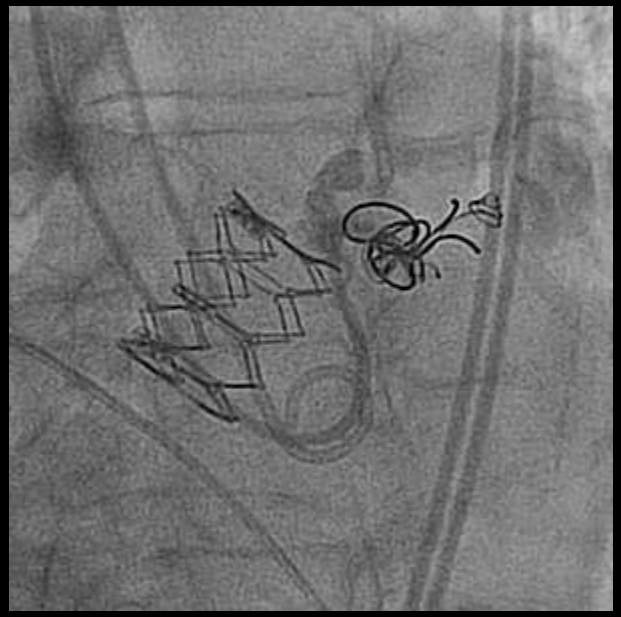

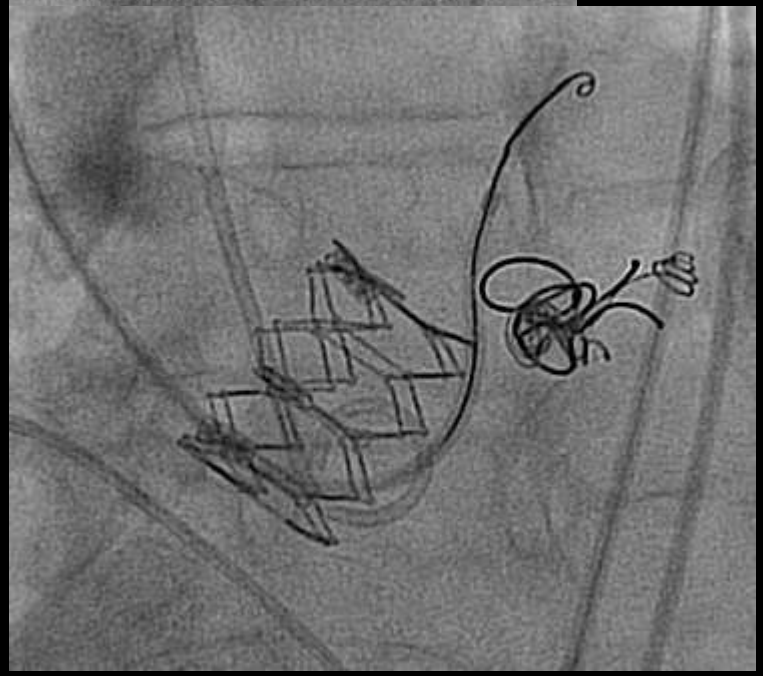

multiple 0.035” Vortex (BSC) coils deployed in pericardium with cessation of bleeding. Drained and partially re-infused 1000cc

Severe tortuosity

Predilatation with 25 mm balloon

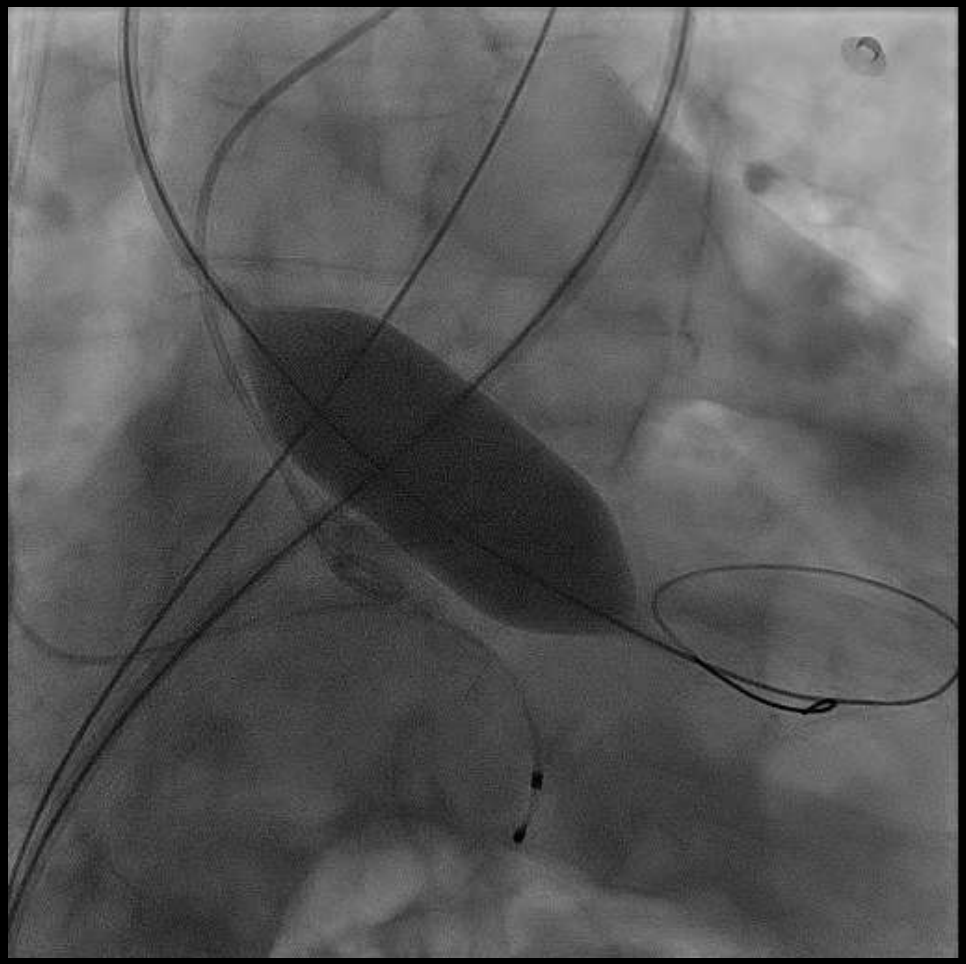

Difficulty to cross the native valve

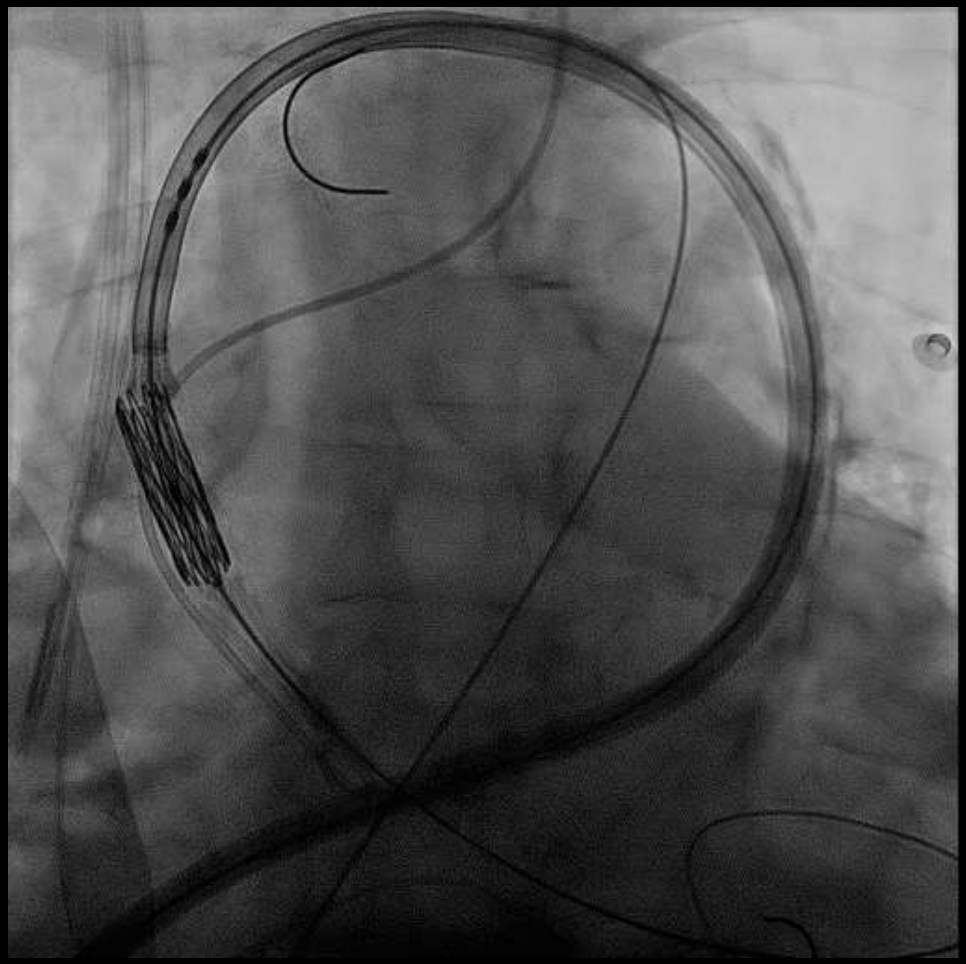

Sudden hemodynamic collapse during crossing of the valve

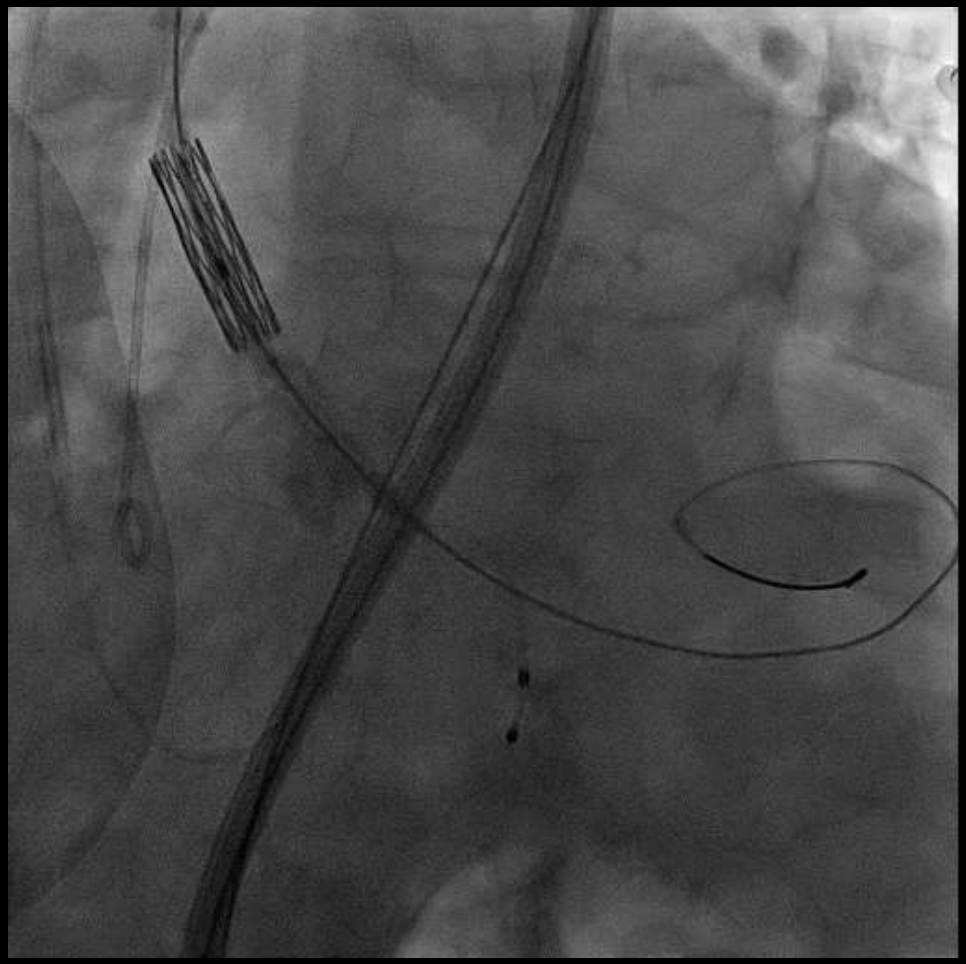

Cardiac tamponade-> immediate pericardiocentesis and fluid resuscitation

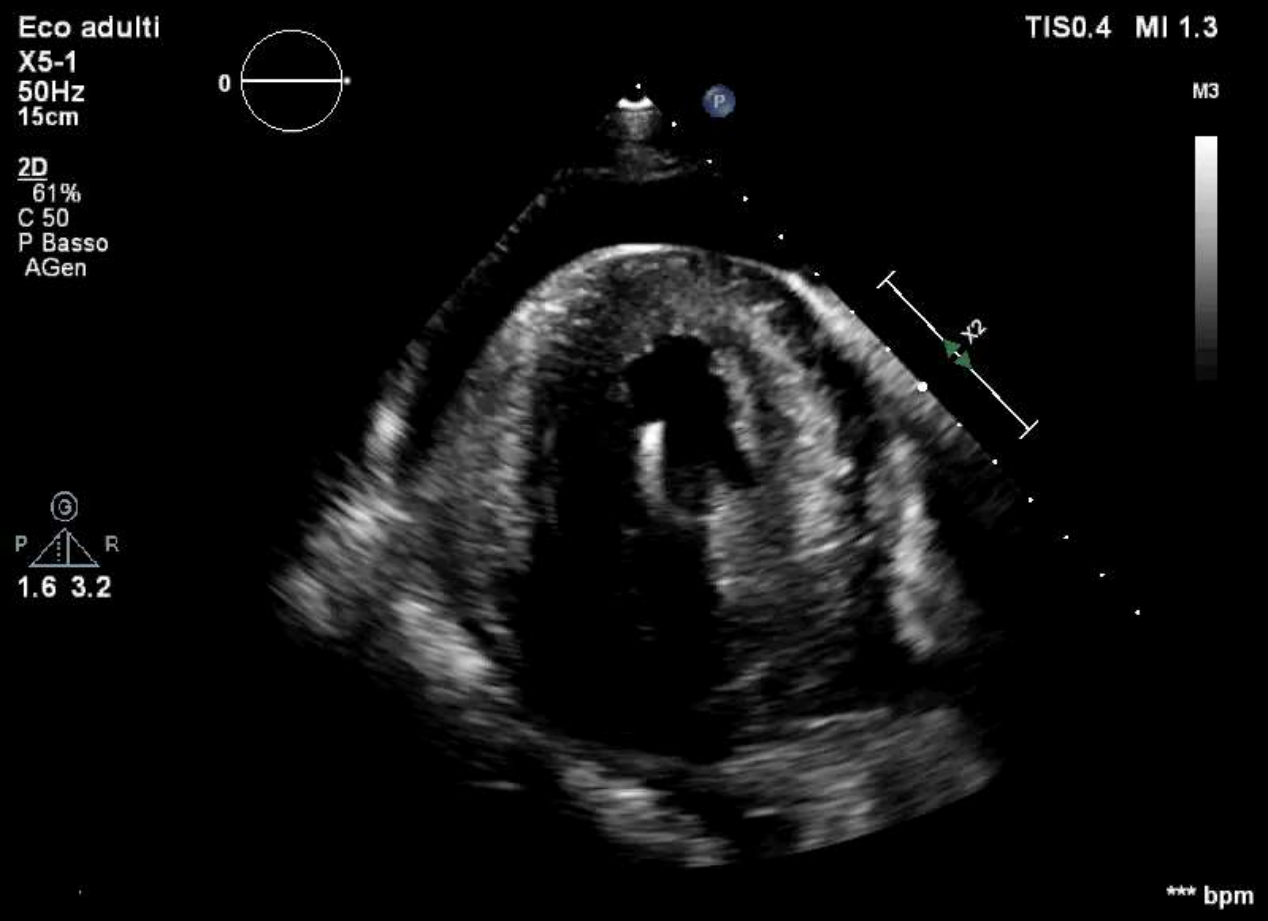

Free wall aortic rupture

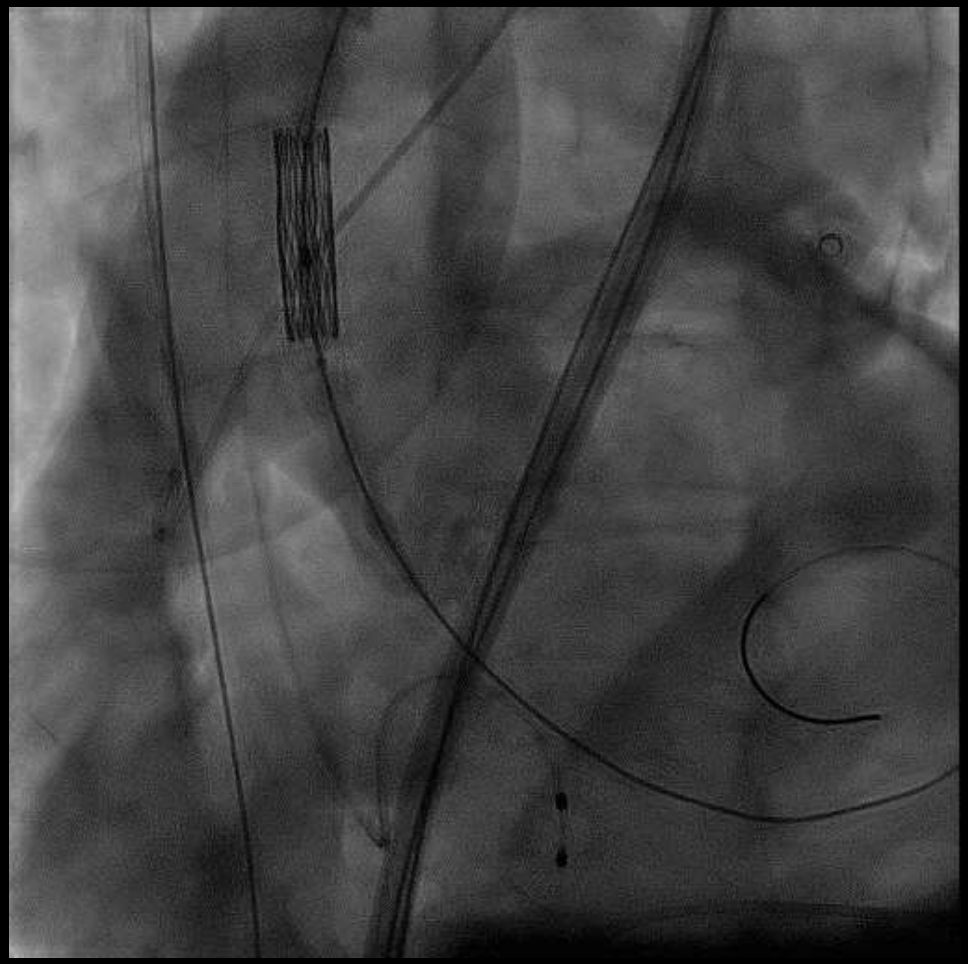

Management of annular rupture

If annular rupture is not complete (periannular staining) observation and conservative management are sufficient

In some conditions: implantation of a second valve may help

For massive ruptures: pericardiocentesis and immediate OR transfer or surgery in the cath. lab should be done .
ECMO as first line should not be considered

Other Oversizing complications

- Coronary obstruction
- Atrio-ventricular block
- Mitral valve injury
- Peri-aortic hematoma
- Septal rupture
- Aortic root rupture

For balloon expandable valves or active expansion the criteria to follow to prevent overexpansion are:

Avoid >10% predicted annular area oversizing

Avoid >5% predicted annular area oversizing in patients with adverse root features :

- *Moderate to severe left ventricular outflow tract calcification*
- *Shallow sinuses of Valsalva*
- *Extreme age*
- *Prior chest irradiation*
- *Small body size*
- *Bicuspid with dilatation of the ascending aorta*

In situations with severe calcifications especially LV outflow consider

Avoid a balloon expandable valve

If you are using a balloon expandable valve perform aortic injection during predilatation and decide size or under filling

Coronary occlusion

Coronary occlusion occurs at the time of postdilatation. The lower the need for postdilatation the lower the risk.

Exception is when implanting a Balloon Expandable valve. In this condition valve implantation is practically synonymous of post-dilatation.

Any valve which may require predilatation or postdilatation is exposed to this risk

Management of coronary occlusion

Guide catheter access and stenting of the occluded vessel

When the implanted valve is a self expandable one: gooseneck valve retrieval to the ascending aorta

If everything not successful: ECMO and CABG

Prevention

Extensive protrusion and TWO stents on each side

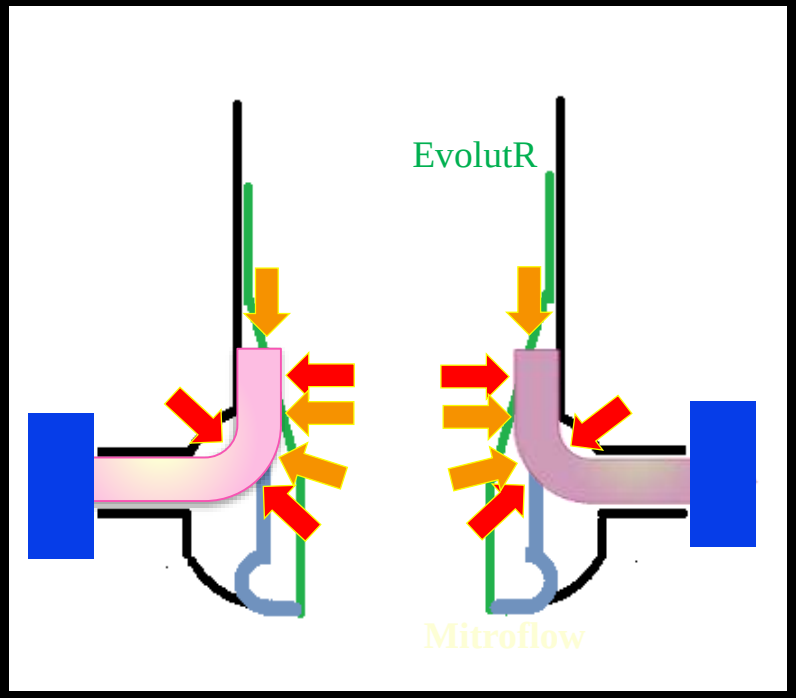

Slight protrusion

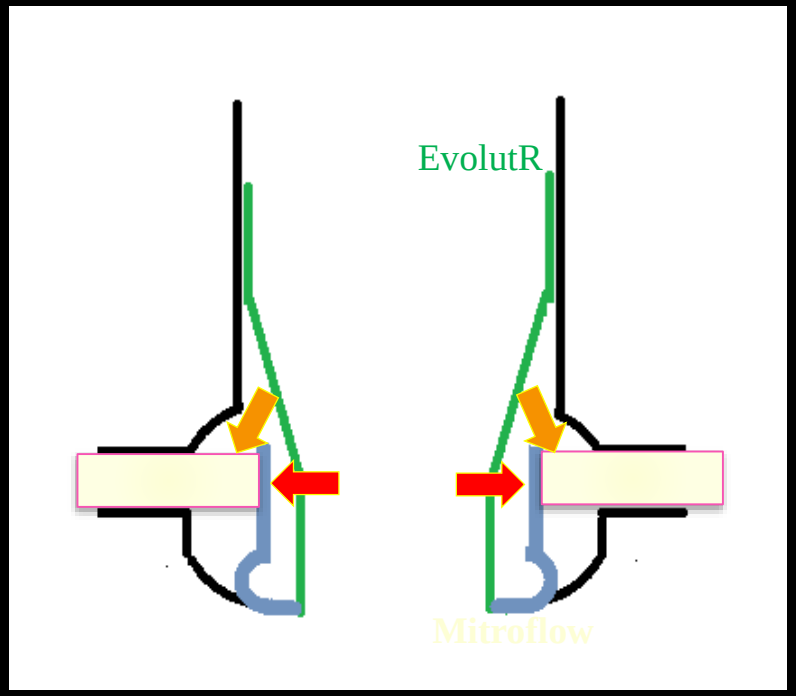

Follow-up still unclear: we need a better approach
BASILICA a possible solution but complex

LV perforation

New TAVI dedicated wires such as:
Safari small/medium (Boston Scientific)
Confida (Medtronic) may prevent this complication

Even if LV perforation is rare always be ready to handle

Surgical action in the cath. lab (preferred) or transfer the patient in the OR

ECMO as a first line should not be considered

Strokes after TAVR

All neurological events at 30 days and 1 year PARTNER Cohort A Trial (*ITT*)

Smith CR, ACC 2011, NEJM in press

Major Stroke: CoreValve study

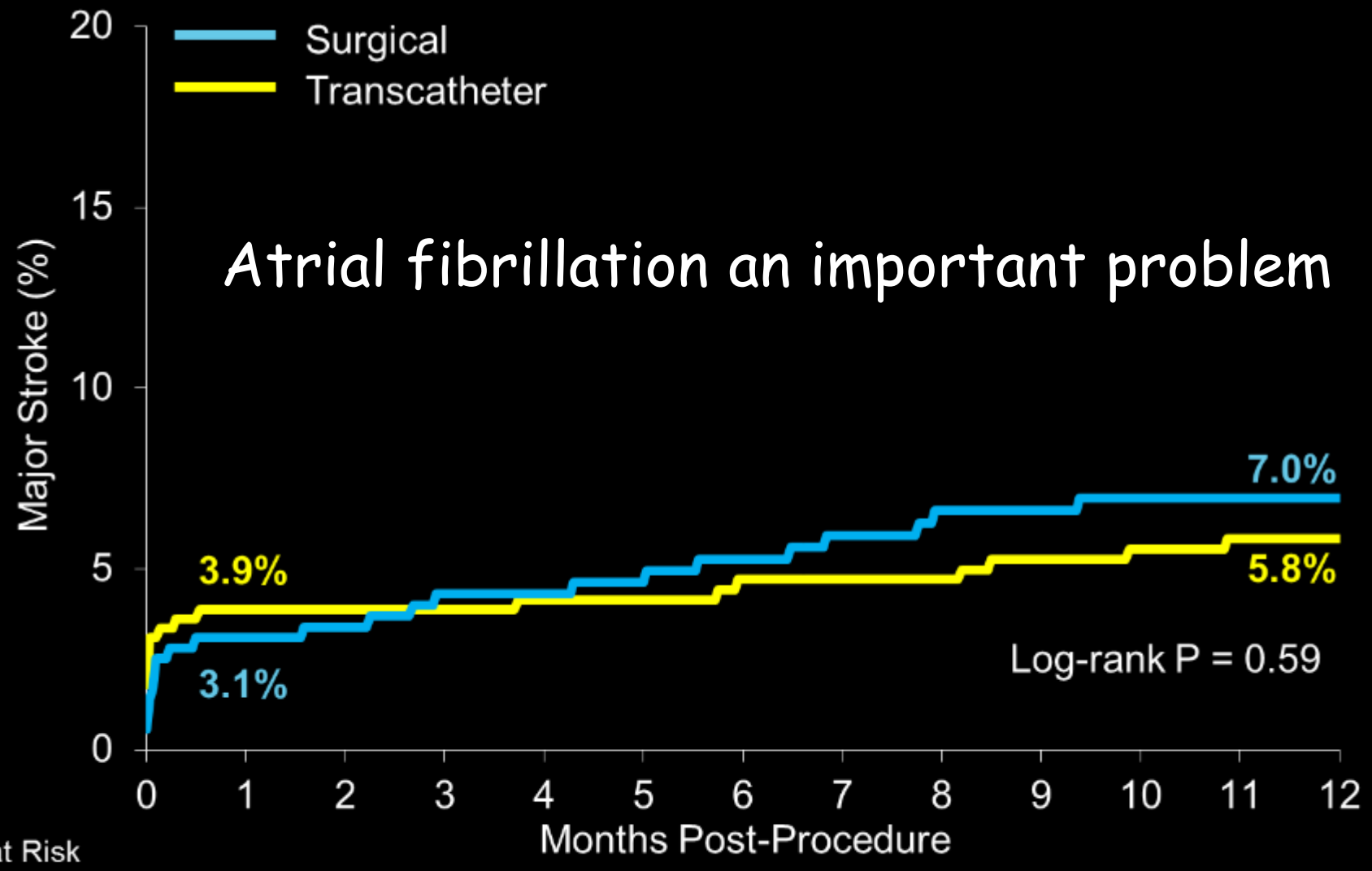

Atrial fibrillation an important problem

No. at Risk				
Surgical	357	333	289	263
Transcatheter	390	367	344	322

EMO GVM CENTRO

GVM CARE & RESEARCH

THE PARTNER 3 TRIAL

All Stroke

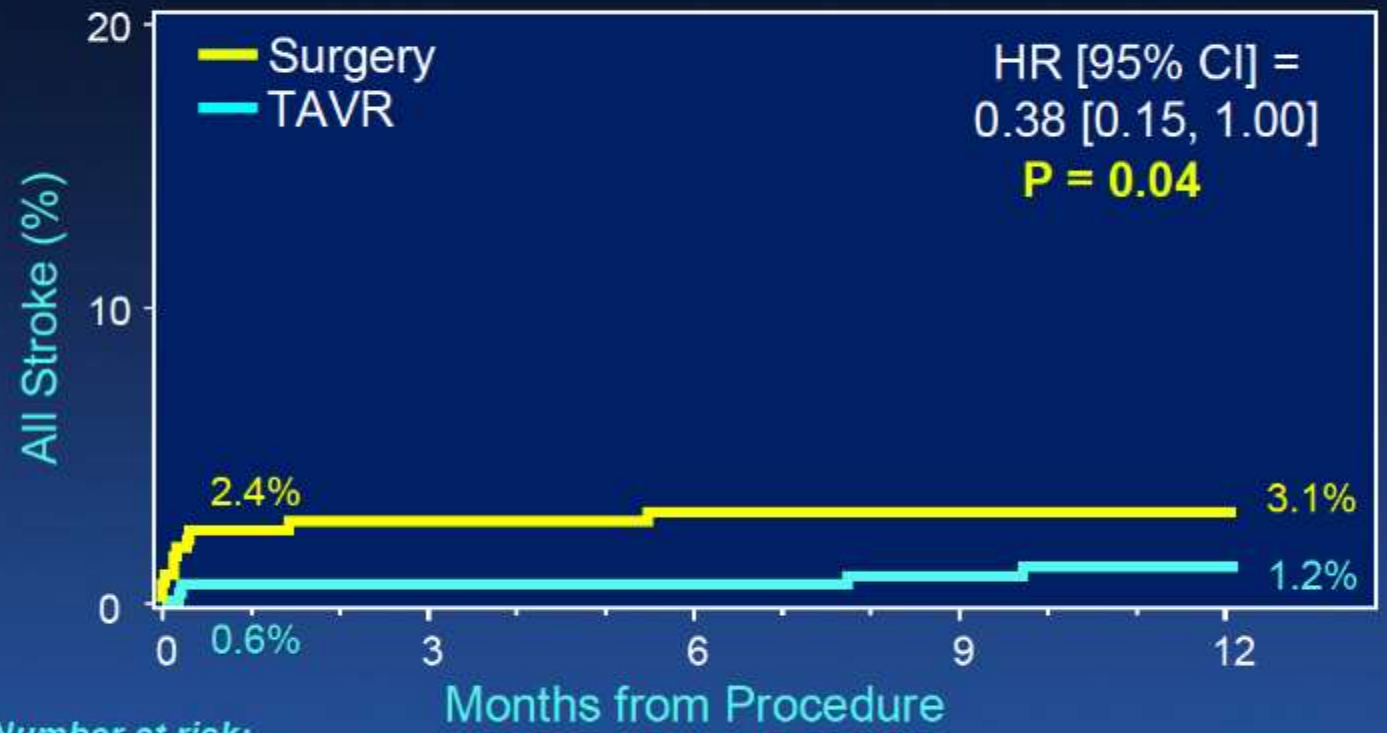

Number at risk:

Surgery	454	435	427	423	421	417
TAVR	496	491	491	489	487	484

Protection devices

They need to be effective and

User Friendly

Paravalvular leaks

Lotus

Sapien 3

Evolute R and PRO

Paravalvular Leak

Moderate / Severe at 30 Days

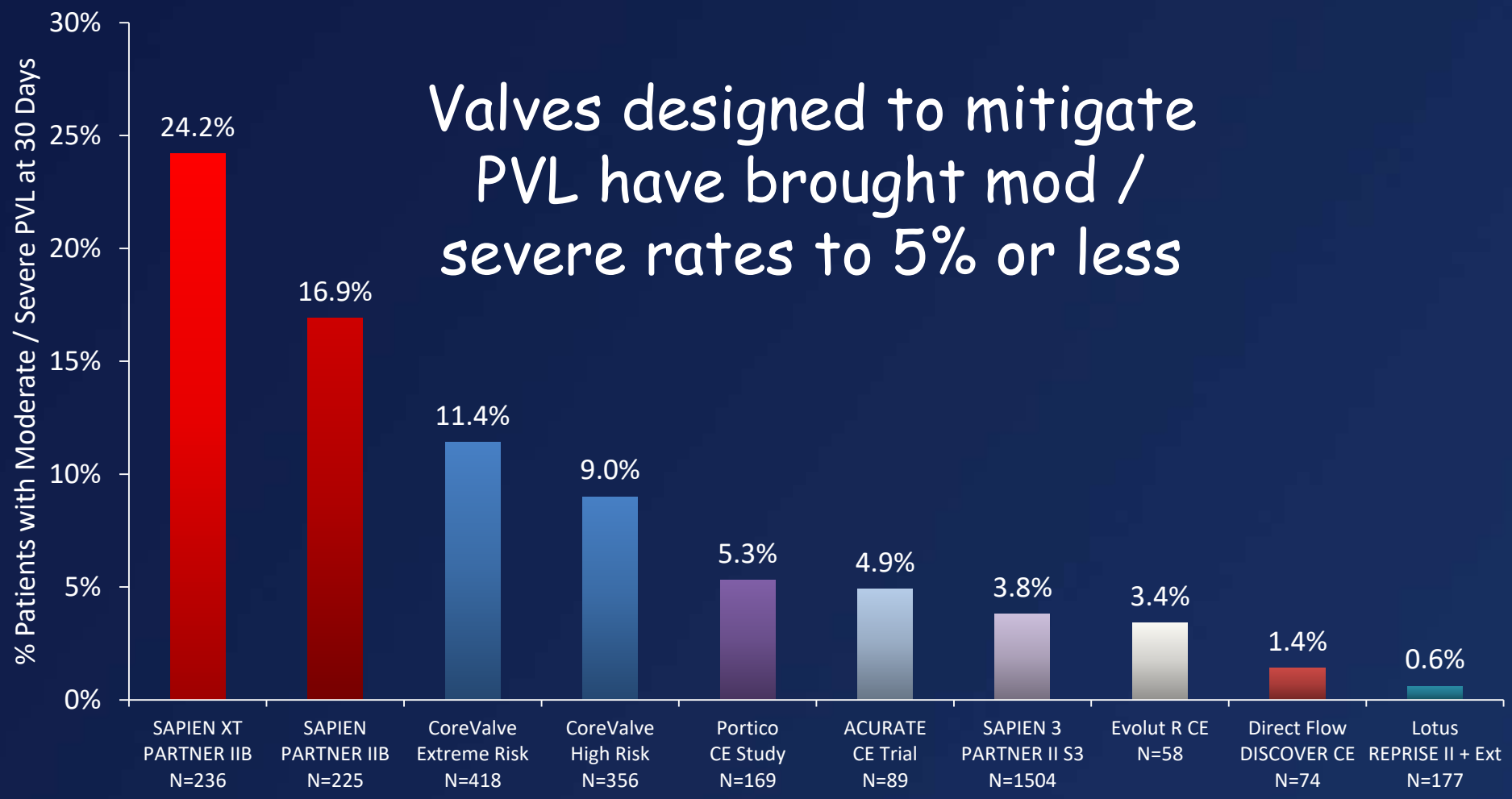

Valves designed to mitigate PVL have brought mod / severe rates to 5% or less

[1]Leon, et. al. presented at ACC 2013; [2]Popma, et al., *J Am Coll Cardiol* 2014; 63: 1972-81; [3]Adams, et al., *N Engl J Med* 2014; 370: 1790-8; [4]Linke, et. al. presented at PCR London Valves 2015; [5]Abizaid, et al., presented at CRT 2015; [6]Kodali, et al., presented at ACC 2015; [7]Manoharan, et al., presented at TCT 2015; [8]Naber, et al., presented at EuroPCR 2015; [9]Vahanian, et al., presented at EuroPCR 2015; [10]Schofer, et al., *J Am Coll Cardiol* 2014; 63: 763-8; [11]Meredith, et al., presented at PCR London Valves 2014

Lessons

1. Many complications may be prevented by patient selection and procedural planning
   - Correct evaluation of peripheral vessels: diameters, calcification, extension of PAD

You cannot afford to create a second complication while solving the first one

aortic occlusion balloon

3. Complications in TAVI patients are unforgiving. Thus always try to prevent them and be ready to deal with them